

PATIENT

Deena Handy

SPECIES

Canine

BREED

Boston Terrier

SEX

FS

AGE

6 years

WEIGHT

21 lbs

INTERPRETED BY

Maggie Machen Lamy,
DVM DACVIM
(Cardiology)

**IMAGING
PERFORMED BY**

Kelly Reschny, CVT

HOSPITAL NAME

Halton Peel Animal
Hospital

REFERRING VET

Dr. Walters

INVOICE

22254

DATE

12/2/21

PRESENTING CLINICAL SIGNS

History: Occasional irregular rhythm.

ELECTROCARDIOGRAPHIC FINDINGS *Note: Single lead ECGs are evaluated as a rhythm strip. Morphology/MEA cannot be definitively commented on.

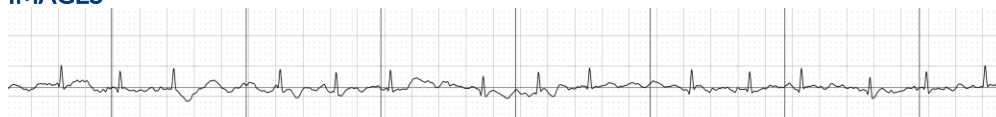
A single lead ECG is available; 25mm/s, 20mm/mV; 2min duration. The average heart rate is 100bpm (range 75-150bpm). P waves are difficult to identify due to low voltage complexes; however, a sinus origin is suspected. The P and QRS morphologies are positive. No ectopic beats, pauses or other dysrhythmias observed.

ECG diagnosis: Normal sinus rhythm with respiratory variation.

INTERPRETATION OF THE FINDINGS & FURTHER RECOMMENDATIONS

The submitted ECG is normal, with no evidence of dysrhythmias. If these findings do not reflect what was ausculted on exam (ie premature beats), a longer recording or hospitalization for ECG monitoring may be necessary.

IMAGES



The information and recommendations provided are based on the images presented by the referring veterinarian. No evaluation can be communicated regarding pathology that was not visible in the image/video clips provided.

Thank you for this referral. If the clinical or image interpretation does not parallel your findings or if I can be of any further assistance please contact me.

Maggie Machen Lamy, DVM
Diplomate of the American College of Veterinary Internal Medicine (Cardiology)
info@sonopath.com